

The Rat Ovaries after Erythropoietin Process

Constantinos Tsompos^{1,*}, Constantinos Panoulis², Aggeliki Triantafyllou³, George C. Zografos⁴, Evripidis Gerakis⁵, Stergios Gerakis⁵, Apostolos Papalois^{5,6}

¹Department of Gynecology, Anticancer Hospital of Thessaloniki "Theageneio" Thessaloniki, HELLAS (GREECE).

²Department of Obstetrics and Gynecology, Aretaieion Hospital, Athens University, Athens, Attiki, HELLAS (GREECE).

³Department of Biologic Chemistry, Athens University, Athens, Attiki, HELLAS (GREECE).

⁴Department of Surgery, Ippokrateion General Hospital, Athens University, Athens, Attiki, HELLAS (GREECE).

⁵Experimental Research Centre, ELPEN Pharmaceuticals, S.A. Inc., Co., Pikermi, Attiki, HELLAS (GREECE).

⁶European University Cyprus, School of Medicine, Nicosia, CYPRUS.

ABSTRACT

Background: This article presents an experimental model for assessment of Erythropoietin (Epo) effects produced upon post-ischemic damage of ovarian tissue. The results of study were expressed as a combined index calculated from individual pathologic scores of experimental ovarian damages. The panel included 4 distinct histologic variables, those of Ovarian Epithelium edema (OE), Ovarian Congestion (OC), Ovarian epithelium Karyorrhesis (OK) and Oophoritis (OO). Final conclusions were based on the data from 2 independent experimental series with acute ischemia-reperfusion of ovaries produced in female rats, assessing the effects of locally injected Erythropoietin (Epo). Moreover, the proinflammatory cytokine (TNF α) and Malonic Dialdehyde (MDA) were also assayed as biomarkers of oxidative stress. **Materials and Methods:** The study was performed in young Wistar rats. Ovarian ischemia was induced by clamping inferior aorta for 45 min after the laparotomy. Two experimental time points were chosen for assessing the OE, OC and OK, OO and TNF α , MDA scores, i.e., 60 and 120 min after starting the ovarian reperfusion. The groups A and B were served as controls, whereas the groups C and D were administered Epo intravenously. **Results:** The first experimental series showed that Epo has a non-significant enhancing effect for the OE and OC indexes (p -values=0.94) in a subgroup with the histologically "unchanged" state, at a grade of 0.009 [-0.258+0.276]. The second study showed that Epo treatment was associated with a moderate, however, non-significant increase of OK and OO within the animals with "unchanged" state, grade 0.027 [-0.055-0.110] (p -values=0.50). These two studies were co-evaluated since they were obtained in the same experimental setting. Separate calculations were performed for TNF α and MDA scores showing some marginal *unspecified* effects of Epo. **Conclusion:** Epo administration was associated with a trend for enhancement of the 4 histologic variables within the "unchanged" grade group at the score of 0.018 [-0.128+0.165] (p -value=0.80), along with some reduction of the TNF α levels by 22.89% [\pm 15.05%] (p -value=0.12), and non-significant increase of MDA levels by 27.05% [\pm 29.63%] (p -value=0.35). This minimal *antioxidant* effects should be interpreted with caution. Very likely, the antioxidant effects will be more pronounced at later observation terms.

Keywords: Ischemia, Erythropoietin, Ovarian epithelium edema, Ovarian congestion, Ovarian epithelium Karyorrhesis, Oophoritis, Reperfusion.

Correspondence:

Dr. Tsompos Constantinos

Department of Gynecology, Anticancer Hospital of Thessaloniki "Theageneio", 2 Alexandrou Symeonidi Street, Thessaloniki-54007, HELLAS (GREECE).
Email: constantinos1tsompos@gmail.com

Received: 23-10-2023;

Revised: 20-11-2023;

Accepted: 19-12-2023.

INTRODUCTION

Erythropoietin (Epo), a known hematopoietic growth factor, is also studied for its potential protective effects. Preservation of ovarian tissues under the conditions of transient hypoxia has sufficient practical value, due to broad usage of it in certain situations. Thus, 4 histologic variables were assessed in Ovarian Ischemia/Reperfusion (OIR) experiments for this purpose.

The study included a complex mean index from 4 other single individualized pathologic scores of experimental ovarian damages, by 2 couples of these. The 1st couple of variables concerned Ovarian Epithelium edema (OE) and Ovarian Congestion (OC) which were closely enhanced the ischemic histologies, together (p -values=0.94) within the "unchanged" grade 0.009 [-0.258+0.276].¹ The other couple of variables were those of ovarian epithelium karyorrhesis (OK) and Oophoritis (OO) which were also non-significantly enhanced within the "unchanged" grade of the tissue lesion 0.027 [-0.055-0.110] together (p -values=0.50).² Furthermore, Epo statistically significantly decreases ICAM-1 and PECAM-1 expression on HUVEC stimulated by TNF- α ,³ as well Malondialdehyde (MDA) is an indicator of the rate of



DOI: 10.5530/fra.2023.2.14

Copyright Information :

Copyright Author (s) 2023 Distributed under Creative Commons CC-BY 4.0

Publishing Partner : EManuscript Tech. [www.emanuscript.in]

lipid peroxidation.⁴ Both molecules the cytokine (TNF α) and the marker for oxidative stress Malondialdehyde (MDA) were also calculated (Figure 1). Although Epo is met in over 34,186 published biomedical studies, Only a 3.84% of them consider its antioxidant capacities.⁵ The present experimental work tried to co-evaluate these OE, OC, OK and OO variables together and to end up to their outcome totally, from the same rat induced OIR protocol.

MATERIALS AND METHODS

Animal experiments

The experiments were performed in albino female Wistar rats, which consumed food and water *ad libitum* for 7 days prior to the experiments. The details of experimental flowchart, i.e., applied anesthesiological techniques, acidometry, the electrocardiography, oxygen supply and the post-experimental euthanasia are also described in preliminary studies.^{1,2} The rats were 16-18 weeks old, being randomly assigned to four groups each consisting of 10 animals. The study was approved by the institutional Ethics Committee (No. 3693/12-11- 2010 and 14/10-1-2012) being in compliance with Declaration of Helsinki. The study was carried out at the laboratory facilities of Elpen Pharmaceuticals Co. Inc. SA. The measurements of biochemical and antioxidant markers were carried out in an external certified laboratory. Histologic studies were carried out by an experienced clinical pathologist of the Pathology Department at the Medical School, University of Athens.

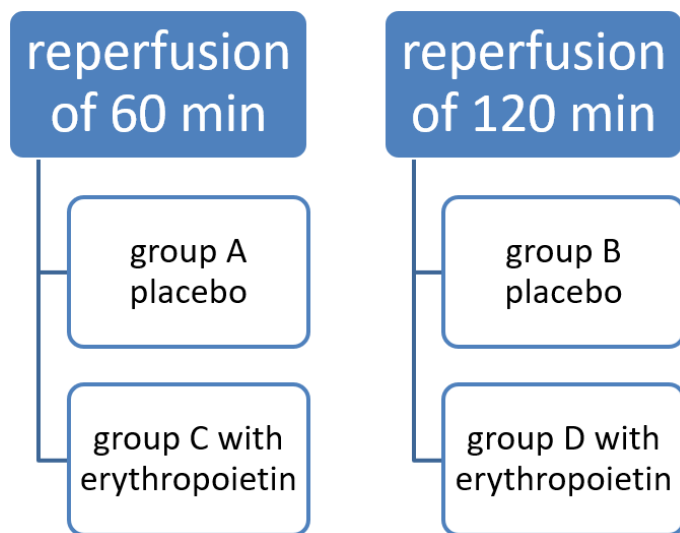
General anaesthesia was provided by initial IM administration of 0.5 mL mix, containing 0,25 mL xylazine, (25 mL, 20 mg/cc), and 0.25 cc ketamine hydrochloride (10 mL, 50 mg/cc). 0.03 cc butorphanol (10 mL, 10 mg/cc) was administered s.c. before laparotomy. Continuous oxygen perioperational supply was administered too. Ischemia was caused by clapping inferior aorta for 45 min after the laparotomy. The organ ischemia was made by

clamping the inferior aorta over the renal arteries with forceps for 45 min. After the blood flow interruption, the protocol of Ovarian Ischemia/Reperfusion (OIR) was applied, as described above for each experimental group. The stage of ischemia were common for all 4 groups. The clamp removal restored the inferior aorta blood flow and provided organ reperfusion. Epo was administered at the time of reperfusion *via* the inferior *vena cava* catheter.

In group A, reperfusion of 60 min was performed; in group B, reperfusion period lasted for 120 min; immediate Epo Intravenous (IV) administration and reperfusion of 60 min was performed in group C; Immediate Epo IV administration and reperfusion for 120 min were conducted in group D. The Epo dose was assessed in preliminary studies as 10 mg/kg body mass. The OE Edema, OC Congestion, OK Karyorrhesis, OO Oophoritis and TNF α , MDA scores were determined at 60th min of reperfusion (for A and C groups) and at 120th min of reperfusion (for B and D groups) Shape 1.

Upon the laparotomy, a surgical excision of the ovaries was made, which were placed in containers with formalin. Along, a small sample of the ovaries was placed in a special container with cold nitrogen for the measurement of antioxidant indexes at an external laboratory performed by a MDA Assay Kit (competitive ELISA) and a Rat TNF alpha ELISA Kit. The formalin-fixed preparations were sent to the Department of Pathology (Medical School, University of Athens). The specimens were treated in standard manner by dehydration at increasing concentrations of ethyl alcohol. The tissue fragments were paraffin-embedded, sliced in a Leica RM2125 RTS microtome and stained by Hematoxylin and Eosin (H&E) and examined under a bright-field microscope. The ovarian epithelium edema was assessed by an experienced pathologist's on the basis of intracellular fluid accumulation degree in ovarian epithelium. The ovarian congestion was assessed by the same person as the presence of an abnormal amount of fluid in ovarian blood vessels or passages. The ovarian epithelium karyorrhesis was determined by *destructive fragmentation, as well as irregular chromatin distribution of the cell nuclei in ovarian epithelium*. Oophoritis was assessed by the degree of white blood cell accumulation within ovarian tissue. The analogue numeric scale was applied to quantify the lesions. In our preliminary studies, the individualized pathological scores were graded as follows: (1) unchanged (0-0.499); (2) mild lesions (0.5-1.499); (3) moderate tissue damage (1.5-2.499); and (4) sufficient tissue lesions (2.5-3) according to LWW classification.⁶ Alternatively, the "unchanged" term, could be replaced by the "lesion-free" one.

As a control (EPO-nontreated) group, a series of 20 control rats was used already since the preliminary experiments of the study. Each of 2 experimental groups (A to B) included 10 rats, for different reperfusion terms (Table 1). The 20 EPO-treated rats were similarly divided into groups C and D.



Shape 1: Setting flowchart

Statistical analysis

cOS is the numerical mean of OE&OC scores and the OK&OO ones, as a typical average. The OE&OC scores arose by the numerical mean of OE scores and OC scores available in references of older published preliminary studies.^{1,2} The OK&OO scores arose by the arithmetic mean of OK scores and OO scores written down in older published preliminary studies, as determined by the original histology studies. Every cOS group score was compared with each other from 3 remained groups applying Wilcoxon signed-rank test. Then, the Generalized Linear Models (GLM) were applied, with dependent variable the cOS scores, and independent variables (1) with or (0) without Epo administration, reperfusion time and their potential interaction. A Generalized Linear Model (GLM) is a flexible generalization of ordinary linear regression, which correlates the expected values (here the histologic values, TNF α , and MDA) of a given unknown quantity (the response variable, a random variable) as a linear combination of a set of observed values (predictors).

Every cOS group score was compared with each other from 3 remained groups applying Wilcoxon signed-rank test (Table 2). Then, the Generalized Linear Models (GLM) were applied with dependant variable the cOS scores and independent variables the Epo administration or no, the reperfusion time and their interaction.

RESULTS

No correlation was revealed between the animal's body mass and OEdeema scores (p -value=0.08), like as no with OCongestion (p -value=0.10), OKarrhyorexis (p -value=0.93), OOphoritis presence (p -value=0.39), nor with TNF α (p -value=0.60) and MDA levels (p -value=0.46).

EPO administration was followed by non-significant enhancement of the 4 histologic variables within the "unchanged" grade and score by 0.012 [-0.264+0.289] (p -value=0.97) according to both glm and Wilcoxon signed-rank tests (Table 3). Similarly, reperfusion terms were non-significantly associated with 4 histologic variables within the "unchanged" grade and score of 0.112 [-0.137+0.362] (p -value=0.39), after co-calculation of these parameters (Table 3). Totally, Epo administration and reperfusion time showed a non significant enhancement of the four 4 histologic variables within the "unchanged" grade, with a score of 0.018 [-0.128+0.165] (p -value=0.80) (Table 3). Similar calculations were performed for TNF- α (Table 4) and MDA (Table 5) variables.

DISCUSSION

Sevim Tuncer *et al.* documented⁷ that both benfotiamine and N-acetylcysteine are equal and effective agents in protection of ovarian tissue against ischemic neovascularization injury in rat autologous intraperitoneal ovarian auto transplants. Nuri Yildirim

et al. evaluated⁸ that Ginkgo Biloba (GB) supplementation significantly decreased scores for follicular degeneration, vascular congestion, edema, hemorrhage, and leukocyte infiltration in an experimental tissue MDA and plasma pentraxin-3 levels based ovarian torsion/de-torsion IR injury rat model. Mohammed Al-Sadawi *et al.* concluded⁹ that women of a relatively younger age may be at 83.3% risk for developing myocardial infarction and cardiac thrombosis approximately 23 days after starting ovarian stimulation medications, although 16.67% of women might be pregnant at presentation. 25% of patients underwent coronary angiography and were treated with percutaneous coronary intervention, since Ovarian Hyperstimulation Syndrome (OHSS) is characterized by increased vascular permeability and hypercoagulable states resulting in strokes and peripheral ischemia. Meryem Kurek Eken *et al.* invented¹⁰ that etanercept which is widely used in autoimmune diseases for blocking the known inflammatory cytokine Tumor Necrosis Factor α (TNF- α), could attenuate inflammation and related oxidative stress and also help to preserve ovarian reserve, reduce tissue 8-OHdG, caspase-3 activity, AMH levels; but significantly increase the numbers of follicles in OIR damage. Fatma Beyazit *et al.* evaluated¹¹ the effects of adalimumab, an antitumor necrosis factor- α antibody, attenuated induced OIR injury, possibly suppressed inflammation, inhibited oxidative stress and altered apoptotic pathways in a rat model. Atilla Topcu *et al.* showed¹² that Metformin (MET) application was effective in preventing damage in ovarian tissue by reducing levels of Reactive Oxygen Species (ROS), proinflammatory cytokines caspase-3 and NF- κ β levels and apoptosis in female Sprague Dawley rats. Cenk Nayki *et al.* found¹³ that rutin (a flavonoid glycoside) significantly ameliorated the induced OIR injury via its possible antioxidative and anti-inflammatory effects, calculating the MDA, TNF- α , IL-1 β , COX-2, tGSH, COX-1 levels in Wistar albino female rats. C Turkler *et al.* invented¹⁴ that lutein ameliorates the induced OIR injury by its antioxidative and anti-inflammatory activities increasing antioxidant enzymes, decreased total glutathione and COX-1 levels in Lutein OIR (p <0.05) tissues of animals. Marwa M M Refaie *et al.* attributed¹⁵ protective effect of Pioglitazone (PIO), anti-inflammatory, anti-apoptotic and anti-oxidant properties; since it reduced non significantly the induced increased ovarian tissue levels of MDA, NO $_x$, gene expressions of p53, TNF α , iNOS, GSH, HO-1 levels, PPARY, eNOS gene expressions and the marked ovarian edema, hemorrhage and congestion associated with cell injury in an OIR experiment. Banu Güleç *et al.* made¹⁶ the assumption that preoperative Progesterone (PG) treatment might exert non-significant protective effects on OIR injury through its anti-apoptotic and antioxidative properties; since serum and tissue TOS levels and histologic scores were significantly lower and tissue TAS levels were higher in treated group (p <0.001).

The present experiment shows that Epo attenuates the cytokine TNF α level which is involved in systemic inflammation. This is one of the cytokines that make up the acute phase reaction,

Table 1: Ovarian Epithelium Edema (OE), Ovarian Congestion (OC), Ovarian Epithelium Karyorrhexis (OK) and Oophoritis (OO) and their mean and SD scores (n=10 in each experimental group).

Experimental groups	Mean OE&OC score \pm SD	Mean OK&OO score \pm SD	Mean OE&OC&OK&OO score \pm SD
Group A (60 min. reperfusion)	Mild lesions 1.15 \pm 0.783	Unchanged 0.05 \pm 0.158	Mild lesions 0.6 \pm 0.428
Group B (120 min. reperfusion)	Moderate lesions 1.5 \pm 0.816	Unchanged 0.1 \pm 0.316	Mild lesions 0.8 \pm 0.404
Group C (Epo+ 60 min. reperfusion)	Mild lesions 1.3 \pm 0.586	Unchanged 0	Mild lesions 0.65 \pm 0.293
Group D (Epo+ 120 min. reperfusion)	Mild lesions 1.35 \pm 0.579	Unchanged 0.15 \pm 0.241	Mild lesions 0.75 \pm 0.390

Table 2: The values difference for groups after Wilcoxon signed-rank test for all histologic variables mean scores.

Intergroup differences	Difference	p-value
A-B	+0.125	0.28
A-C	+0.175	0.75
A-D	+0.1	0.44
B-C	+0.05	0.30
B-D	-0.025	0.75
C-D	-0.075	0.43

Table 3: The deteriorating influence of erythropoietin for all histologic variables in connection with reperfusion time.

Alteration	95% Confidence interval	Reperfusion time	p-value
Unchanged+0.087	-0.319 - +0.494	1 hr Epo	0.62
Unchanged+0.012	-0.264 - +0.289	1.5 hr Epo	0.97
Unchanged -0.012	-0.363 - +0.338	2 hr Epo	0.81
Unchanged+0.112	-0.137 - +0.362	Placebo reperfusion	0.39
Unchanged+0.018	-0.128 - +0.165	Interaction	0.80

Table 4: The attenuating effect of erythropoietin on TNF α levels in connection with reperfusion time.

Alteration	Standard deviation	Reperfusion time	p-value
-28.66%	\pm 117.05%	1 hr Epo	0.44
-28.86%	\pm 109.00%	1.5 hr Epo	0.24
-29.05%	\pm 84.43%	2 hr Epo	0.28
-45.73%	\pm 103.02%	Placebo reperfusion	0.06
-22.89%	\pm 15.05%	Interaction	0.12

Table 5: The enhancing effect of erythropoietin on MDA levels in connection with reperfusion time.

Alteration	Standard deviation	Reperfusion time	p-value
95.61%	\pm 264.16%	1 hr Epo	0.27
69.33%	\pm 211.73%	1.5 hr Epo	0.15
43.06%	\pm 126.42%	2 hr Epo	0.29
-25.41%	\pm 211.08%	Placebo reperfusion	0.59
27.05%	\pm 29.63%	Interaction	0.35

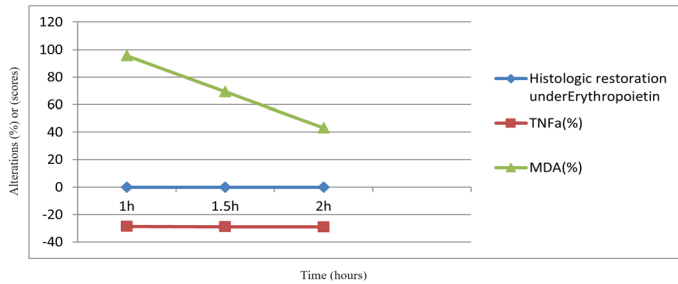


Figure 1: The alterations of TNFa, MDA and histology versus time.

stimulates phagocytosis and the production of IL-1 oxidants and thus attenuates all of these procedures by 22.89% [$\pm 15.05\%$] (p -value=0.1246). Also, Epo declines the MDA levels, which is a marker for oxidative stress and specifically of lipid peroxidation in tissues; thus optimistic trends appear, since assess the membrane damage by 27.05% [$\pm 29.63\%$] (p -value=0.3518). Moreover, a numerical meta-analysis of the reperfusion-dependent Epo effects upon the complex of 35 serially made variables of the blood counts and chemistry markers from similar experimental setting has also shown some marginal increase in their total scores.¹⁷

CONCLUSION

Similar results suggest that, in addition to stimulating RBC and fetal hemoglobin production, Epo might alleviate symptoms of hemolytic anemias as an antioxidant,¹⁸ as well as to produce some protective effects, e.g., in experimental renal injuries.¹⁹ An insignificant trend for deterioration of histologic variables was noticed (+0.018 [-0.128+0.165] grade “unchanged”, which is non-significant after the short-term Epo administration and reperfusion time together, as it enhanced the complex mean index from 4 other single individualized pathologic scores (p -value=0.80). However, the antioxidant capacity is probable from the results on TNFa and MDA levels. Hence, it challenges for further research about its beneficial usage in protection of ovarian tissue against ischemic neovascularization injury in autologous intraperitoneal ovarian auto transplants, preservation of ovarian reserve following OIR damage induced or in ovarian torsion/de-torsion IR injury and ovarian stimulation. The minimal antioxidant effects should be interpreted with caution. Very likely, the antioxidant effects will be more pronounced at later reperfusion terms.

ACKNOWLEDGEMENT

This study was funded by Scholarship by the Experimental Research Centre ELPEN Pharmaceuticals (E.R.C.E), Athens, Greece. The research facilities for this project were provided by the aforementioned institution.

CONFLICT OF INTEREST

The authors declare that there is no conflict of interest.

REFERENCES

- Tsompos C, Panoulis C, Toutouzias K, Triantafyllou A, Zografos CG, Tsarea K, et al. The Co-Evaluation of Ovarian epithelium Edema and Congestion after the erythropoietin effect on Ovarian ischemia reperfusion injury. *J Gen Genet Eng.* 2019; 3(1): 1-7.
- Tsompos C, Panoulis C, Toutouzias K, Triantafyllou A, Zografos G, Tsarea K, et al. The co-evaluation of ovarian epithelium karyorrhexis and oophoritis after the erythropoietin effect on ovarian ischemia reperfusion injury. *Am Res. J Biomed Eng.* 2019; 2(1): 1-8.
- Szczepeński M, Kamianowska M, Wnuczko K, Pietruczuk M, Wołczyński S. The influence of erythropoietin (Epo) on intercellular adhesion molecule-1 (ICAM-1, CD54) and platelet-endothelial cell adhesion molecule-1 (PECAM-1, CD31) expression on human umbilical vein endothelial cells (HUVEC) induced by tumor necrosis factor-alpha (TNF-alpha). *Wiad Lek.* 2007; 60(1-2): 22-7. PMID 17607964.
- Kaçmaz A, Polat A, User Y, Tilki M, Ozkan S, Sener G. Octreotide improves reperfusion-induced oxidative injury in acute abdominal hypertension in rats. *J Gastrointest Surg.* 2004; 8(1): 113-9. doi: 10.1016/j.gassur.2003.09.026, PMID 14746843.
- Search results-PubMed. Update. 3.2.2024. “https://pubmed.ncbi.nlm.nih.gov/?term=erythropoietin” erythropoietin - Search Results - PubMed (nih.gov) update. 03.02.2024.
- Available from: lww.classification.update.03.02.2024
- Tuncer S, Atılgan R, Pala S, Kuloğlu T, Artaş G, Aydın S. N-acetylcysteine and Benfotiamine protect auto transplanted ovarian tissue from ischemia-reperfusion injury: an experimental study. *Exp Clin Transplant.* 2018; 5. doi:10.6002/ect.2017.0320.
- Yildirim N, Simsek D, Kose S, Yildirim AGS, Guven C, Yigitirur G, et al. The protective effect of *Ginkgo biloba* in a rat model of ovarian ischemia/reperfusion injury: improvement in histological and biochemical parameters. *Adv Clin Exp Med.* 2018; 27(5): 591-7. doi:10.17219/acem/68896, PMID 29790691.
- Al-Sadawi M, Chowdhury R, Asun S, Ray J, Soni L, Bahtiyar G. Ovarian hyperstimulation syndrome and myocardial infarction: A systematic review. *Int J Clin Endocrinol Metab.* 2019; 5(1): 9-12. doi:10.17352/ijcem.000035.
- Eken MK, Ersoy GS, Kaygusuz EI, Devranoğlu B, Takır M, Çilingir ÖT, et al. Etanercept protects ovarian reserve against ischemia/reperfusion injury in a rat model. *Arch Med Sci.* 2019; 15(4): 1104-12. doi:10.5114/aoms.2017.72406, PMID 31360205.
- Bayazit F, Büyük B, Turkon H, Elmas S, Uzun M. Adalimumab mitigates ovarian ischemia-reperfusion injury in rats by regulating oxidative stress, apoptosis and resolution of inflammation. *J Obstet Gynaecol Res.* 2019; 45(2): 358-67. doi:10.1111/jog.13846, PMID 30358007.
- Topcu A, Balık G, Atak M, Mercantepe T, Uydu HA, Tumkaya L. An investigation of the effects of metformin on ovarian ischemia-reperfusion injury in rats. *Eur J Pharmacol.* 2019; 865(865): 172790. doi:10.1016/j.ejphar.2019.172790, PMID 31730761.
- Nayki C, Nayki U, Keskin Cimen FK, Kulhan M, Yapca OE, Kurt N, et al. The effect of rutin on ovarian ischemia-reperfusion injury in a rat model. *Gynecol Endocrinol.* 2018; 34(9): 809-14. doi:10.1080/09513590.2018.1450378, PMID 29564969.
- Turkler C, Kulhan NG, Ata N, Kiremitli T, Cimen FK, Suleyman H. The ameliorative effect of lutein on ovarian ischemia-reperfusion injury in rats. *Bratisl Lek Listy.* 2018; 119(11): 713-7. doi:10.4149/BLL_2018_127, PMID 30686005.
- Rafaie MMM, El-Hussieny M. Protective effect of pioglitazone on ovarian ischemia reperfusion injury of female rats via modulation of peroxisome proliferator activated receptor gamma and heme-oxygenase 1. *Int Immunopharmacol.* 2018; 62: 7-14. doi:10.1016/j.intimp.2018.06.037, PMID 29966944.
- Bağır BG, Taşkın Mİ, Adalı E, Öztürk E, Hismoğulları AA, Yay A. Does progesterone have protective effects on ovarian ischemia-reperfusion injury? *J Turk Ger Gynecol Assoc.* 2018; 4(19): 2: 87-93. doi:10.4274/jtgga.2017.0047.
- Tsompos C, Panoulis C, Toutouzias K, Triantafyllou A, Zografos G, Papalois A. The effect of erythropoietin on chloride levels during hypoxia reoxygenation injury in rats. *Signa Vitae.* 2017; 13(2): 97-101. doi:10.22514/SV132.112017.15.
- Amer J, Dana M, Fibach E. The antioxidant effect of erythropoietin on thalassemic blood cells. *Anemia.* 2010; 2010: 978710. doi: 10.1155/2010/978710, PMID 21490911.
- Katavetin P, Tungsanga K, Eiam-Ong S, Nangaku M. Antioxidative effects of erythropoietin. *Kidney Int Suppl.* 2007;(107):S10-5. doi: 10.1038/sj.ki.5002482, PMID 17943138.

Cite this article: Tsompos C, Panoulis C, Triantafyllou A, Zografos CG, Gerakis E, Gerakis S, et al. The Rat Ovaries after Erythropoietin Process. *Free Radicals and Antioxidants.* 2023;13(2):86-90.